

208. Outer side of left Knee. The Edinburgh Stereoscopic Atlas of Anatomy. Lower limb. Surface anatomy - N°4.

Numéro d'inventaire : 1979.26251.16

Type de document : photographie

Éditeur : Edinburgh Stereoscopic Anatomy, T.C. & E.C. Jack (34, Henrietta St., London, W.C. Edinburgh, London)

Période de création : 1er quart 20e siècle

Date de création : 1900 (vers)

Description : Epreuves stéréoscopiques positives gélatino-argentiques contrecollées sur un carton rigide contenant un texte descriptif (format du carton : 230 x 180). Série rangée dans un emboîtement en carton sous forme de reliure en deux parties avec la mention "Pestalozzi Stereographs. Anatomy" sur la tranche.

Mesures : hauteur : 90 mm ; largeur : 180 mm

Notes : Descriptif : genou gauche (anatomie).

Mots-clés : Méthodes pédagogiques actives (y compris la coopération scolaire, classes vertes, méthode Freinet)

Pratique pédagogique

Filière : aucune

Niveau : aucun

Autres descriptions : Langue : Français
ill.

THE EDINBURGH STEREOSCOPIC ATLAS OF ANATOMY.

LOWER LIMB.

SURFACE ANATOMY—No. 4.

OUTER SIDE OF LEFT KNEE.

1. **Bony points.**—When the knee is half flexed, the patella forms a projection in front of the lower end of the femur. Behind it, the external condyle forms a projection below the skin.

The prominence on the front of the external condyle is due to the projection of the highest part of the trochlear surface, and this corresponds to the level of the epiphysial plate of cartilage on the outer side.

The external tuberosity of the tibia can very readily be made out when the limb is in this position, and just above it can be felt a depression, at the bottom of which lies the external semilunar cartilage.

The head of the fibula lies at the bottom of a depression rather to the back on the outer side. The shaft of the fibula can only be made out with difficulty, as it is covered by the peroneal muscles.

2. **Muscles and tendons.**—The tendon of the biceps stands out very distinctly, and there is a depression just above it, which is limited by the ilio-tibial band.

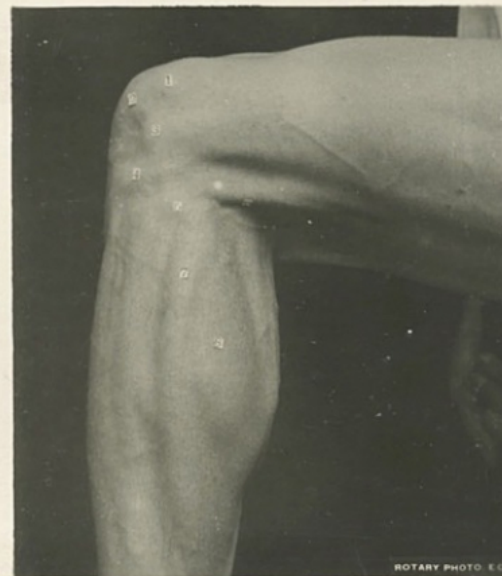
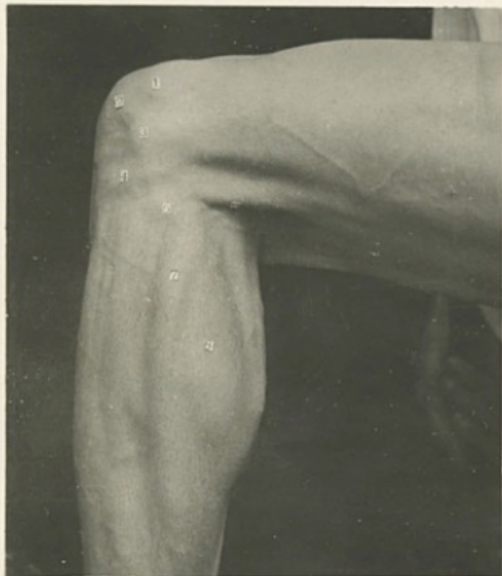The tendon of the semitendinosus, lying on the fleshy semimembranosus, forms an almost equally distinct projection on the inner side of the hollow which corresponds to the popliteal space.

In the leg, the two heads of the gastrocnemius can be seen, with a groove between them, and adjoining the outer head is the prominence formed by the peroneus longus, while in front of that are the extensor longus digitorum and tibialis anticus muscles.

The figures indicate—

- | | |
|---------------------------------|---------------------|
| 1. External condyle, front. | 5. Head of fibula. |
| 2. Patella. | 6. Biceps. |
| 3. External condyle, back part. | 7. Peroneus longus. |
| 4. External tubercle of tibia. | 8. Gastrocnemius. |

LOWER LIMB—SURFACE ANATOMY. No. 4.
EDINBURGH STEREOSCOPIC ANATOMY.
Copyright: T. C. & E. C. Jack, Edinburgh, & 34 Henrietta St., London, W.C.



ROTARY PHOTO. E.C.