
205. Front of Thigh. The Edinburgh Stereoscopic Atlas of Anatomy. Lower limb. Surface anatomy - N°1.

Numéro d'inventaire : 1979.26251.4

Type de document : photographie

Éditeur : Edinburgh Stereoscopic Anatomy, T.C. & E.C. Jack (34, Henrietta St., London, W.C. Edinburgh, London)

Période de création : 1er quart 20e siècle

Date de création : 1900 (vers)

Description : Epreuves stéréoscopiques positives gélatino-argentiques contrecollées sur un carton rigide contenant un texte descriptif (format du carton : 230 x 180). Série rangée dans un emboîtement en carton sous forme de reliure en deux parties avec la mention "Pestalozzi Stereographs. Anatomy" sur la tranche.

Mesures : hauteur : 90 mm ; largeur : 180 mm

Notes : Descriptif : fémur (anatomie).

Mots-clés : Méthodes pédagogiques actives (y compris la coopération scolaire, classes vertes, méthode Freinet)

Pratique pédagogique

Filière : aucune

Niveau : aucun

Autres descriptions : Langue : Français
ill.

THE EDINBURGH STEREOSCOPIC ATLAS OF ANATOMY.

LOWER LIMB.

SURFACE ANATOMY—No. 1.

FRONT OF THIGH.

With this view Scarpa's triangle No 2. should be compared.

1. **Bony points.**—The anterior superior spine of the ilium lies at the bottom of a slight depression, and marks the junction between the abdominal wall and the thigh. The crest of the ilium passes upwards and outwards from it, forming a sinuous depressed line, and Poupart's ligament passes downwards and inwards. These lines form the upper limit of the thigh and the lower limb of the abdomen.

The great trochanter also lies in a depressed area in the outer side of the thigh—the figure 8 is placed in front of it, at the level of its upper border, and this level corresponds to the centre of the head of the femur.

2. **Muscles.**—The sartorius runs downwards and inwards from the anterior superior spine, and is a valuable landmark. To its inner side is the depressed area corresponding to Scarpa's triangle, and to its outer side is a hollow, between the sartorius and the rectus femoris muscles. The lower part of the tensor fasciæ femoris forms a prominence outside this and rather lower down, and the rectus femoris becomes evident in the surface below this point, in the centre of the thigh, and to its outer side is the vastus externus still lower down.

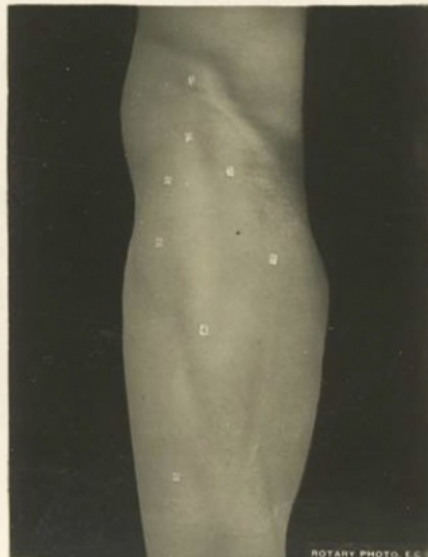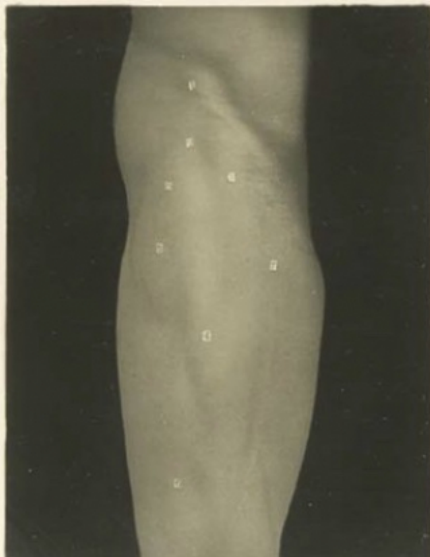
The adductor muscles in the inner side cannot be isolated from one another on the surface.

Vessels.—The figure 7 is placed on the femoral artery near the apex of Scarpa's triangle. The artery higher up lies midway between the anterior superior iliac spine and the pubic symphysis, and passes behind 7 in a line which, continued downwards, goes to the adductor tubercle of the femur.

The figures indicate—

- | | |
|--|---|
| 1. Anterior superior spine. | 5. Tensor fasciæ femoris, lower part. |
| 2. Depression between sartorius and tensor fasciæ femoris. | 6. Vastus externus. |
| 3. Sartorius. | 7. On femoral artery. |
| 4. Rectus femoris. | 8. Level of great trochanter (upper margin) and of head of femur. |

LOWER LIMB SURFACE ANATOMY. NO. 1.
EDINBURGH STEREOSCOPIC ANATOMY
Copyright: T. C. & E. C. Jack, Edinburgh, & J. H. Hensoldt, St. Louis, W.C.



ROTARY PHOTO. E.C.J.